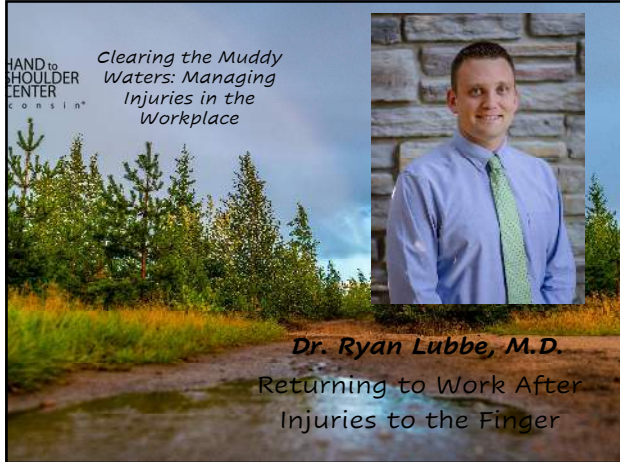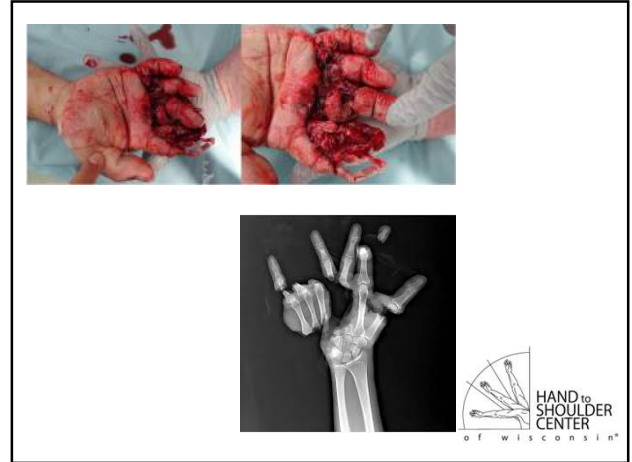
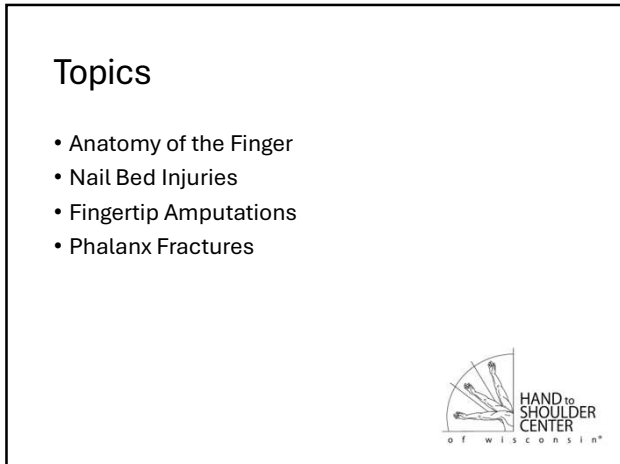


1



2



3



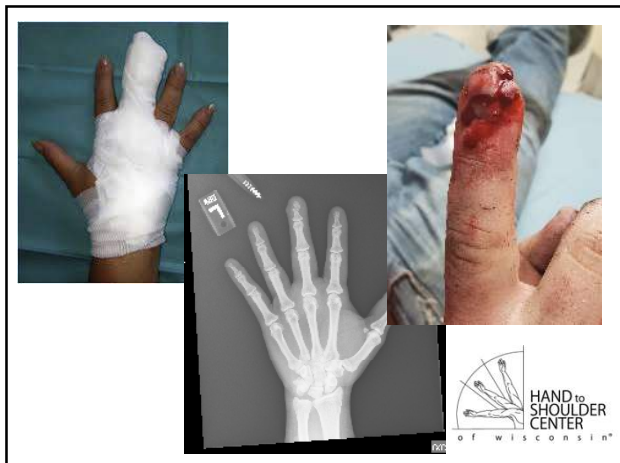4



5



6



7

### Anatomy

- Eponychium
- Paronychium
- Hyponychium
- Nail plate
- Sterile Matrix
- Germinal Matrix

8

### Anatomy

- Distal phalanx located in dorsal half of fingertip
- Extensor tendon inserts 5mm proximal to the germinal matrix
- Germinal matrix originates 1.3 mm distal to the extensor tendon insertion
- Longitudinal growth of nail is 0.1mm/day
- Fingertip important for grip, proprioception, and sensation

9

### Nail Bed Injuries

- Subungual hematoma
- Nail bed laceration
- Nail matrix avulsion

10

### Subungual Hematoma

- Crush injury
- Accumulation of blood under nail plate
- Nail bed injury with intact nail plate
- Painful due to pressure of hematoma under the nail

11

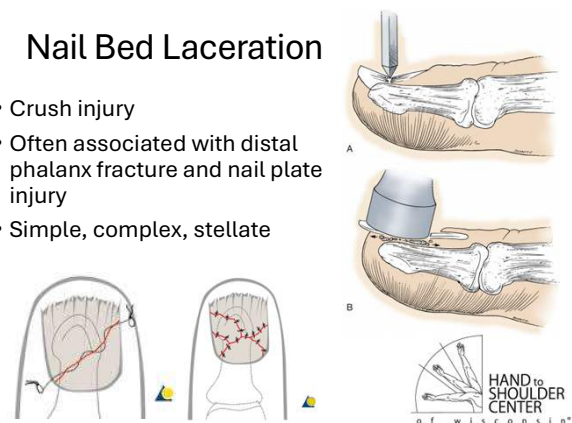
### Subungual Hematoma: Treatment

- <50% involved
  - Observation
  - Trephination (if painful)
- >50% involved
  - Trephination
  - Nail plate removal and nail bed repair
- Trephination
  - Needle
  - Electrocautery

12

### Nail Bed Laceration

- Crush injury
- Often associated with distal phalanx fracture and nail plate injury
- Simple, complex, stellate



The diagrams illustrate different types of nail bed lacerations: a simple laceration (A), a complex laceration (B), and a stellate laceration. Below these are anatomical views of the distal phalanx showing the location of the nail bed and the nail plate.

13

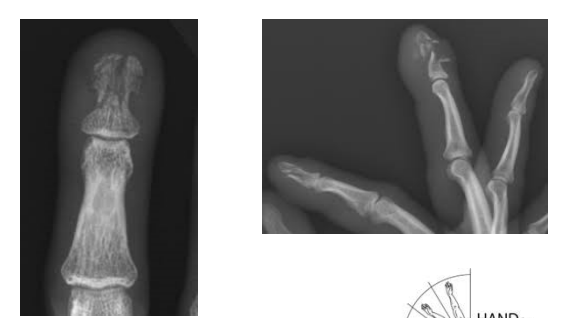
### Nail Bed Laceration



An intraoperative photograph showing a deep laceration of the nail bed. The nail plate is partially avulsed, and the underlying nail bed is exposed and bleeding.

14

### Nail Bed Laceration



Two X-ray images of a hand. The left image is a lateral view of the distal phalanx showing a clear fracture line. The right image is a dorsal view of the hand showing the location of the injury on the distal phalanx.

15

### Nail Bed Laceration: Treatment

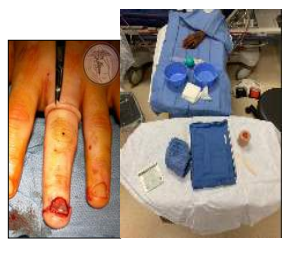


A photograph of a male surgeon in blue scrubs and a surgical cap, standing in an operating room. In the background, another person in scrubs is visible, and medical equipment is present.

16

### Nail Bed Laceration: Treatment

- Antibiotics?
- Digital block
- Digital tourniquet
- Removal of nail plate (freer and hemostat)
- Irrigation and debridement
- Repair with absorbable suture
- Splint eponychial fold

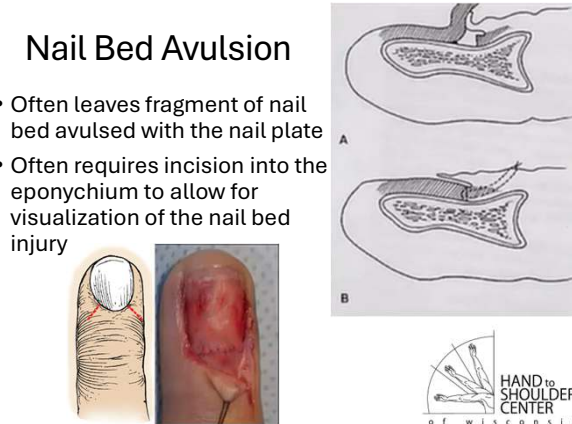


A photograph showing a hand with a nail bed laceration. The nail plate has been removed, and the wound is being prepared for repair. A surgical setup with instruments and a splint is visible in the background.

17

### Nail Bed Avulsion

- Often leaves fragment of nail bed avulsed with the nail plate
- Often requires incision into the eponychium to allow for visualization of the nail bed injury



The diagrams (A and B) show the anatomy of the nail bed and the eponychium. Diagram A shows a normal nail bed, while Diagram B shows an avulsion. Below the diagrams are two photographs: one showing a hand with a nail bed avulsion and another showing a close-up of the surgical site with an incision made into the eponychium.

18

## Nail Bed Injuries

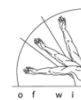- Return to work
  - Post op 3-5 days: OT for dressing change, tip protector, ROM
    - Immobilize DIP joint if fracture is pinned
  - Post op 2 wk: suture removal (if needed)
  - Post op 4 wk: pin removal (if fracture)
  - Return to full duty: 2-4 wk (no fracture), 4-6 wk (fracture)
  - \*New nail growth 6-9 months



19

## Fingertip Amputations

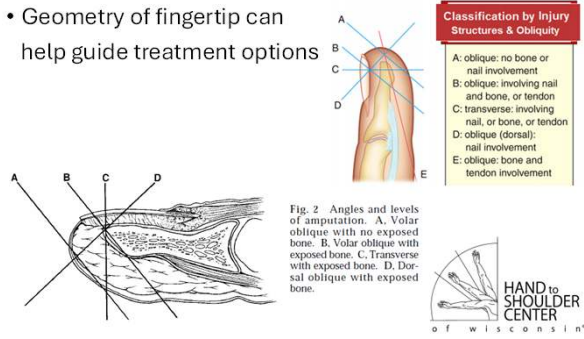
- Goals of treatment:
  - Preservation of durable skin coverage
  - Preservation of useful sensibility
  - Preservation of length
  - Avoidance of symptomatic neuromas
  - Prevention of adjacent joint contractures
  - Allow for early return to work



20

## Fingertip Amputations

- Geometry of fingertip can help guide treatment options



21

## Fingertip Amputations: Treatment

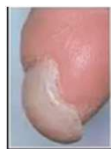- Primary closure/revision amputation
- Secondary intention
- FTSG
- Integra
- Local-Regional Flaps
- Pedicled Flaps



22

## Primary Closure: Revision Amputation

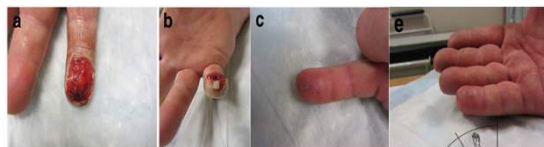
- Indicated for partial amputations with exposed bone
- Shortening of bone with rongeur
- Digital nerves placed on traction and cut to decrease risk of painful neuroma
- Maintain bony support of nail bed to prevent hook nail
- Nail bed ablation may be required



23

## Secondary Intention

- Best with wounds <1cm
- Healing occurs by re-epithelialization over 3-4 weeks
- Daily dressing changes
- Heals with normal sensation



24

HAND (2014) 9:282-288  
DOI: 10.1007/s11552-014-9663-5

REVIEW

**Secondary healing of fingertip amputations: a review**

Emily M. Krauss · Donald H. Lalonde



- Time to healing: 4 weeks
- Time off work: patients can return within 1 week




25

### Integra

- Can be placed over bone or tendon of fingertip
- Sutured in place and bolstered
- Removed 3 weeks after placement
- FTSG (1 week later) vs. secondary intention

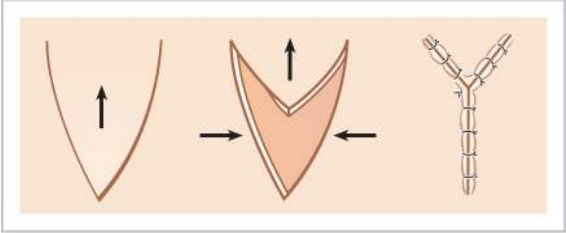

26

### Integra



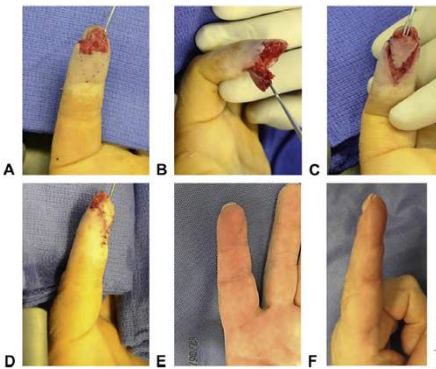


27

### V-Y Advancement

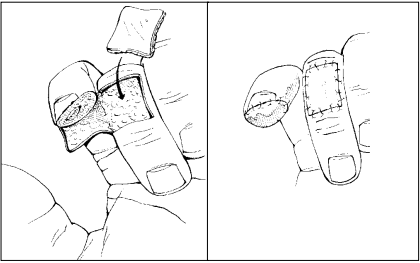

28

### V-Y Advancement

29

### Cross-Finger Flap

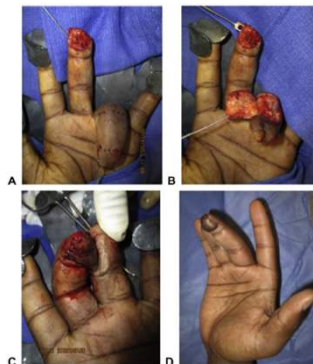30

### Cross-Finger Flap



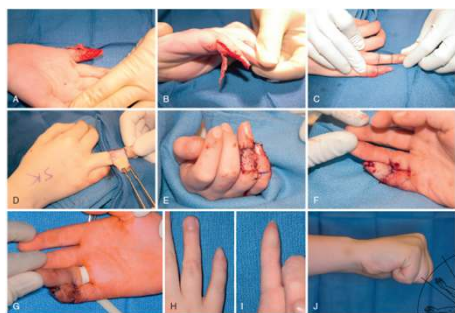
31

### Cross-Finger Flap



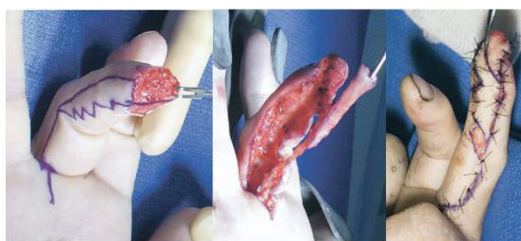32

### Cross-Finger Flap



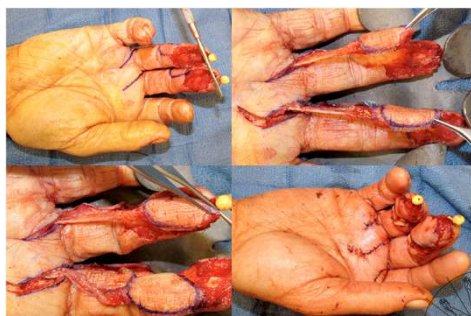33

### Homodigital Island Flap



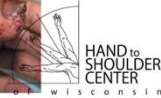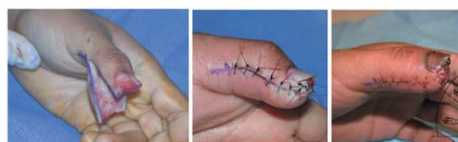
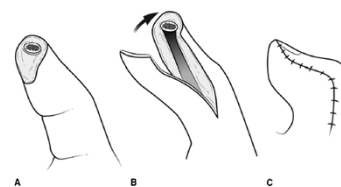
34

### Homodigital Island Flap



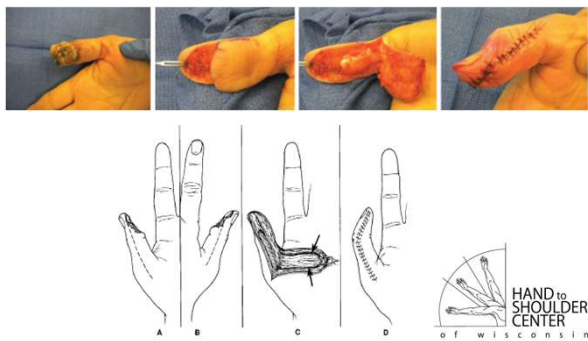
35

### Moberg Advancement Flap



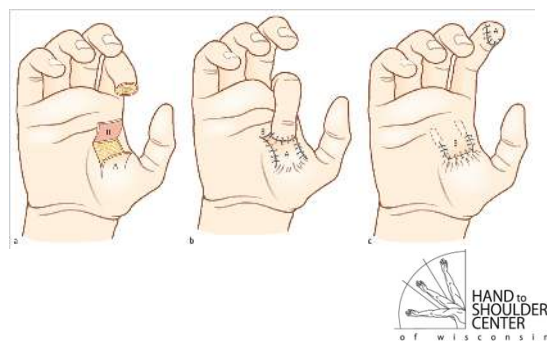
36

### Moberg Advancement Flap



37

### Thenar Flap



38

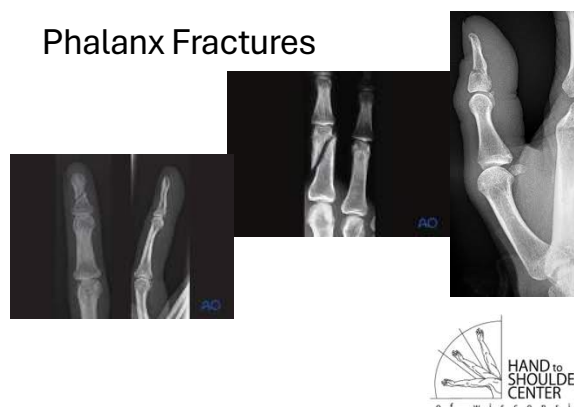### Fingertip Amputations

- Return to work
  - Revision amputation
    - Post op 3-5 days: OT for dressing change, tip protector, ROM
    - Post op 2 wk: suture removal
    - Return to full duty: 2-4 wk
  - Other
    - Post op 2 wk: suture removal
    - Post op 3 wk: silicone removal (Integra), division of flap (cross finger)
    - Return to full duty: 2-8 wk

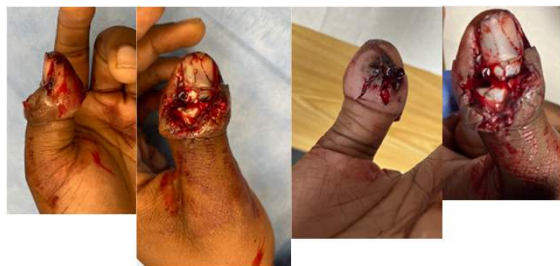

39

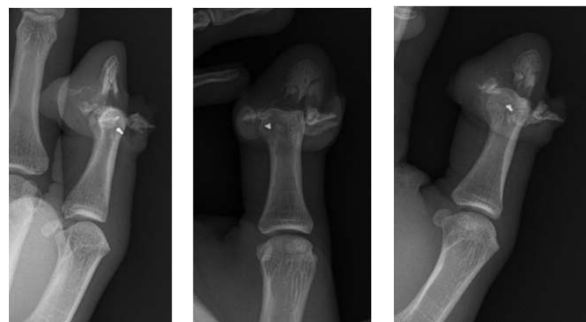
### Phalanx Fractures



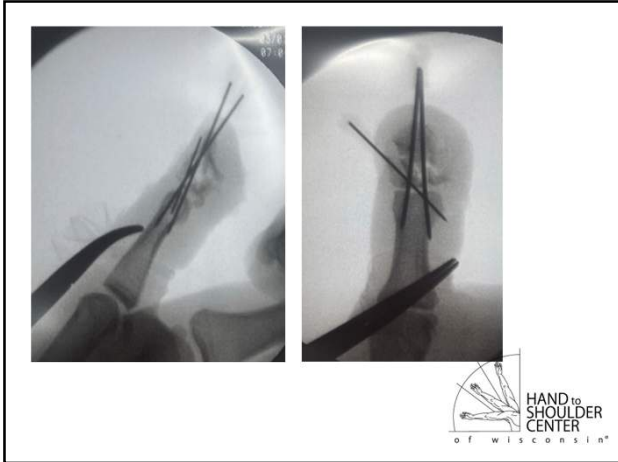
40



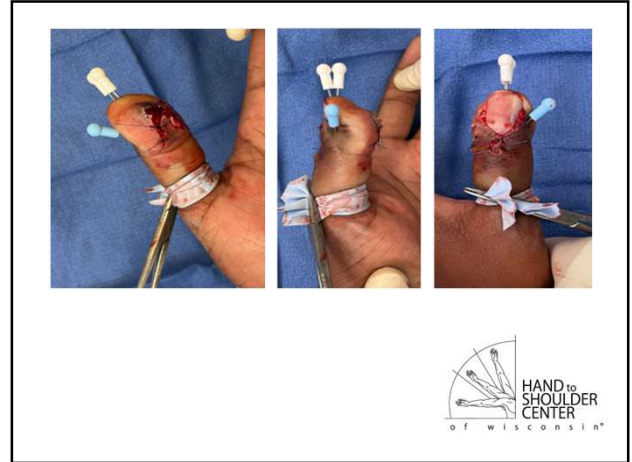
41



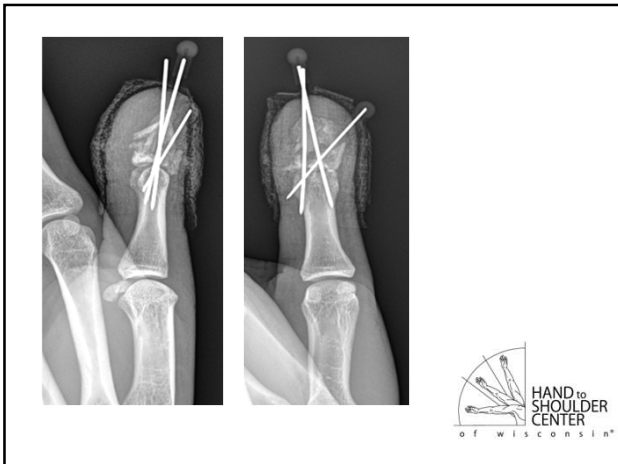
42



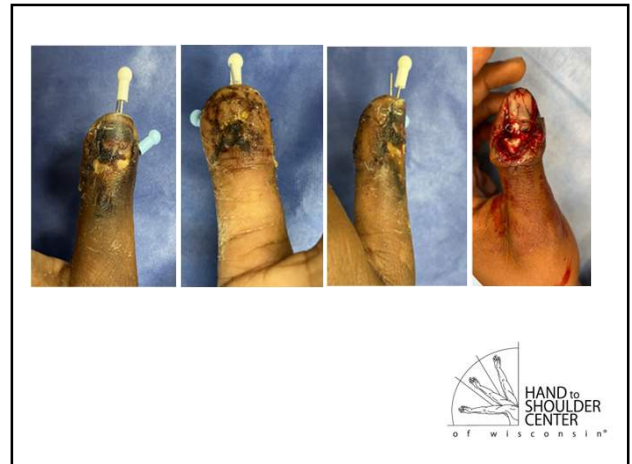43



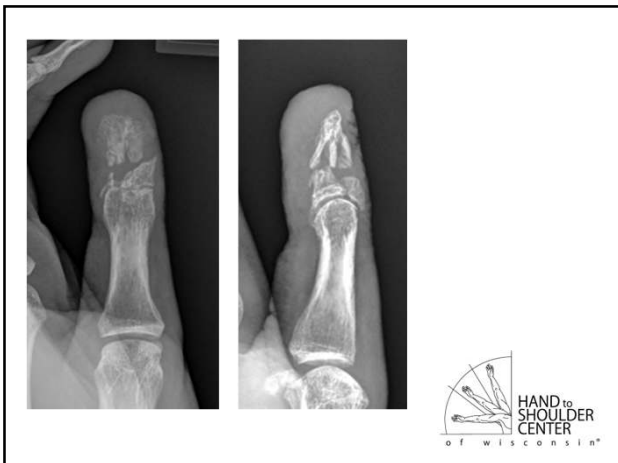44



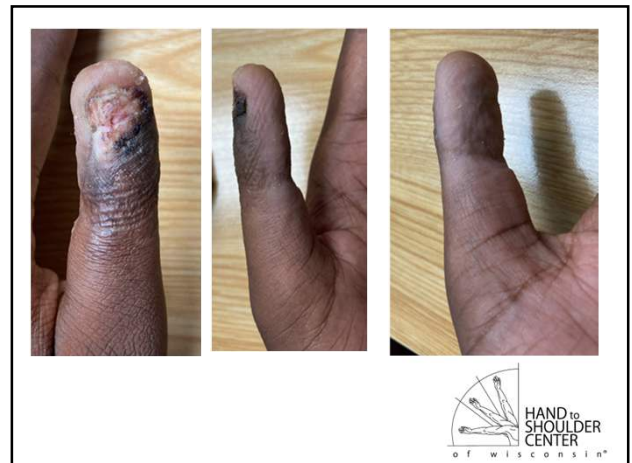45



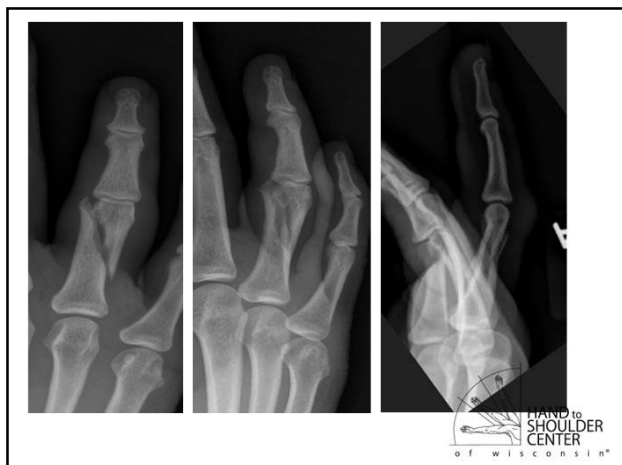46



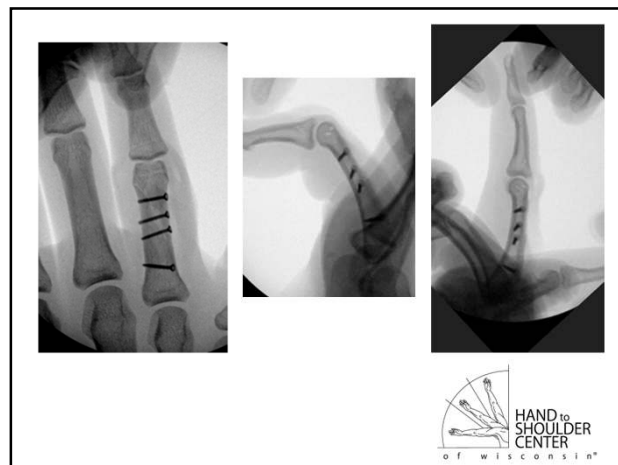
47



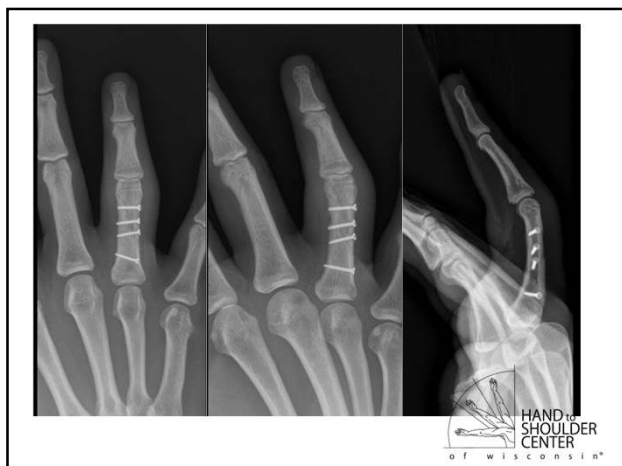48



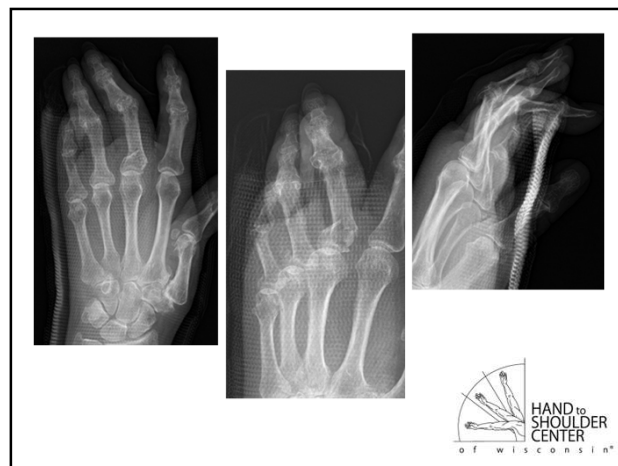49



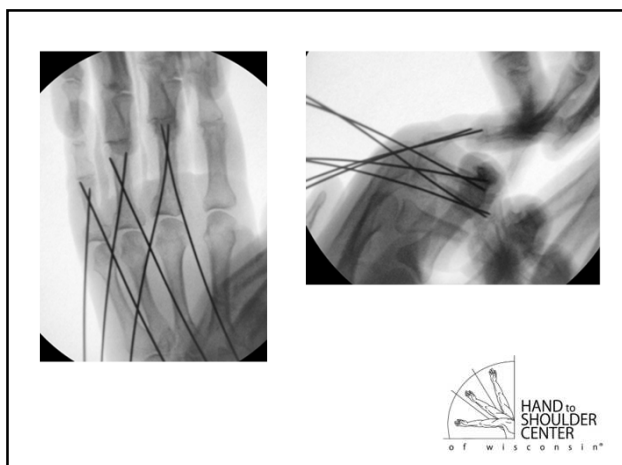
50



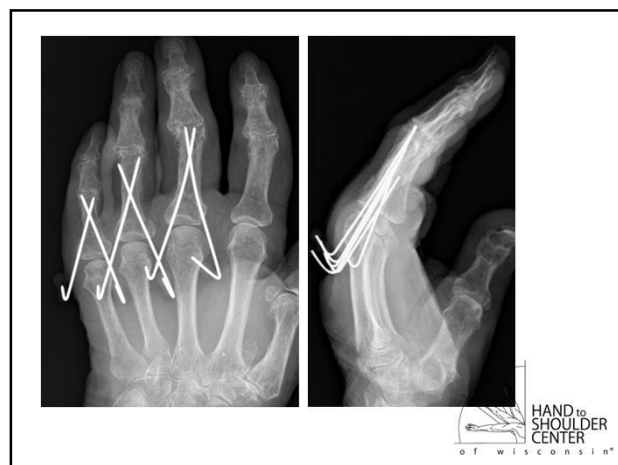
51



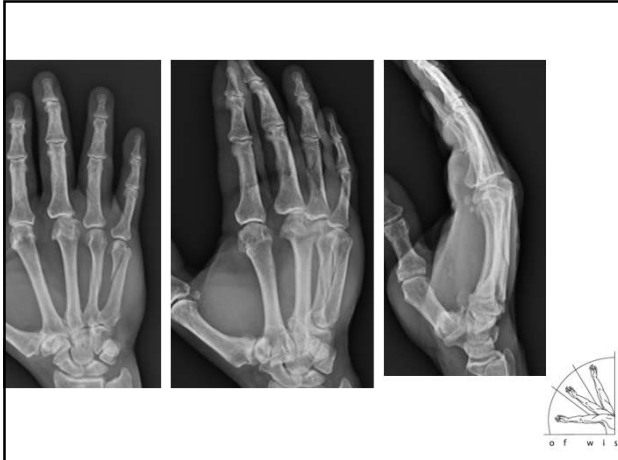52



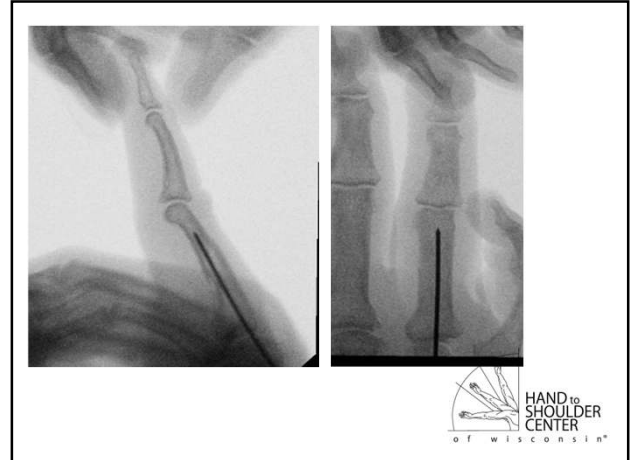
53



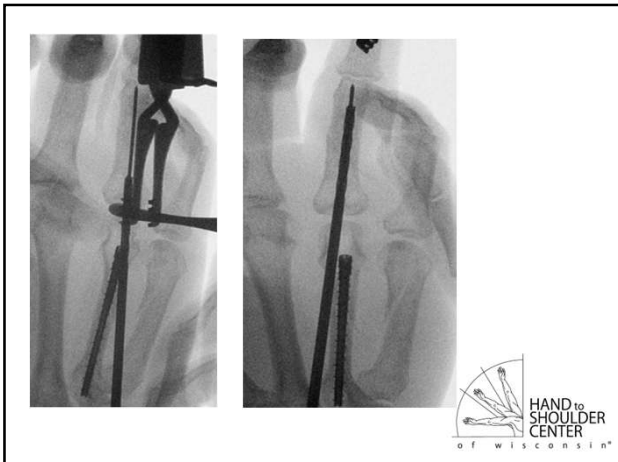
54



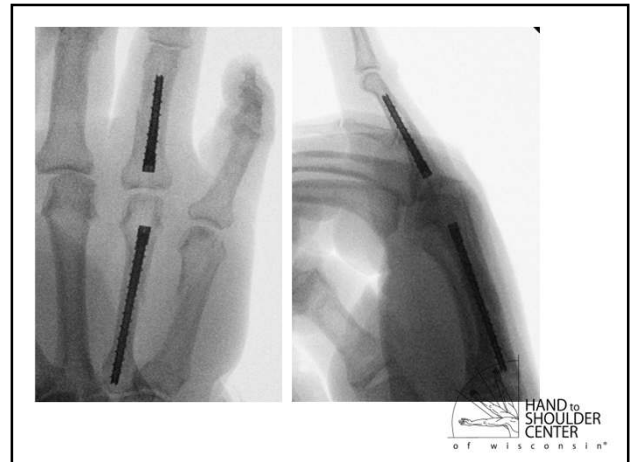
55



56



57



58

## Phalanx Fractures

- Return to work
  - Post op 3-5 days: OT for dressing change, splint, ROM
  - Post op 2 wk: suture removal (if needed)
  - Post op 4-6 wk: pin removal (if needed)
  - Return to full duty: 6-8 wk



59

# THANK YOU!



60